



**PRESENTING CLINICAL SIGNS**

History: Grade II/VI murmur first noted 6 months ago. Muffled heart sounds. BNP 1118. BCS 7/9.

**DATE**

1/28/22

**ECHOCARDIOGRAPHIC FINDINGS**

2D, M-mode, and Doppler study.

**PERFORMED BY:**

Dr. VanCampen

There is mild left atrial dilation. The mitral valve is normal. Left ventricular wall thickness is normal. Left ventricular internal dimensions are normal. Left ventricular systolic function is hyperdynamic. The aorta and aortic valve are normal. Right atrial and right ventricular dimensions are normal. The tricuspid valve is normal. The pulmonary artery and pulmonic valve are normal. No shunting lesions are visualized. No pericardial effusion or cardiac masses are seen.

**INTERPRETED BY**

Keith Blass, DVM,  
MS, DACVIM  
(Cardiology)

ECG during echo: Sinus rhythm

LA - 16.4 mm  
LA/Ao - 1.52  
IVSd - 5.0 mm  
LVPWd - 4.9 mm  
LVIDd - 11.8 mm  
LVIDs - 4.1 mm  
FS - 65%  
LVOT - 1.10 m/s  
RVOT - 0.82 m/s

**PATIENT**

Lochinvar Heartwood

**SPECIES**

Feline

**ASSESSMENT/RECOMMENDATIONS**

**BREED**

This examination demonstrates mild dilation of Lochinvar's left atrium, with differentials for this finding including a restrictive cardiomyopathy (RCM), atrial myopathy, and cardiac thyrotoxicosis. As only mild dilation is present, Lochinvar's current risk for the development of congestive heart failure and/or thromboembolic disease appears to be relatively low, despite the significant increase in his BNP level.

**DLH**

**SEX**

No reason for Lochinvar's muffled heart sounds is appreciated in this exam, though his increased body condition score could potentially be the cause.

**MN**

A T4 level is recommended.

**AGE**

8 y

No therapy is recommended based on this exam.

A recheck echocardiogram is recommended in ~6 months. Thoracic radiographs are recommended if Lochinvar experiences respiratory clinical signs.

**WEIGHT**

6.89 kg

**HOSPITAL NAME**

Mississippi Mills AH

**REFERRING VET**

Dr. VanCampen



DATE

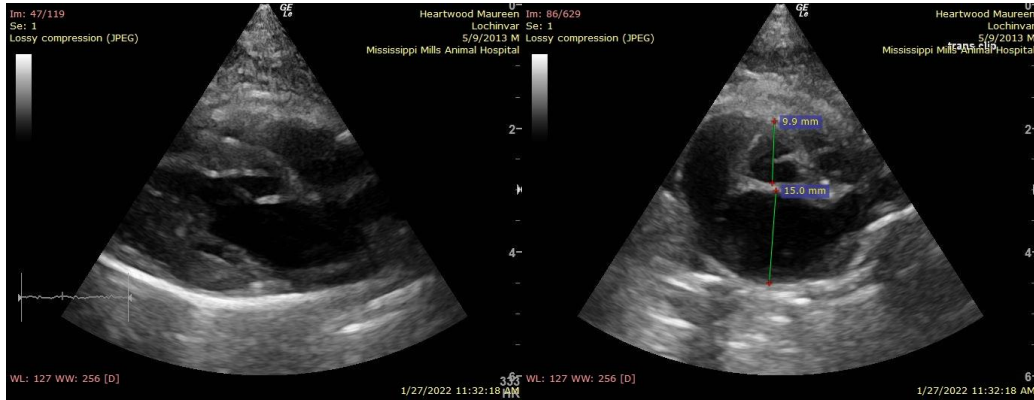
1/28/22

PERFORMED BY:

Dr. VanCampen

INTERPRETED BY

Keith Blass, DVM,  
 MS, DACVIM  
 (Cardiology)



**The information and recommendations provided are based on the images presented by the referring veterinarian. No evaluation can be communicated regarding pathology that was not visible in the image/video clips provided.**

PATIENT

Lochinvar Heartwood

Thank you for this referral. If the clinical or image interpretation does not parallel your findings or if I can be of any further assistance please contact me.

SPECIES

Feline

**Keith Blass, DVM, MS, DACVIM (Cardiology)**  
 KeithBlass@gmail.com  
 631-804-5754

BREED

DLH

SEX

MN

AGE

8 y

WEIGHT

6.89 kg

HOSPITAL NAME

Mississippi Mills AH

REFERRING VET

Dr. VanCampen